REVIEWS

Inflammation in venous disease

P. ZAMBONI [1], S. LANZARA [1], F. MASCOLI [1], A. CAGGIATI [2], A. LIBONI [1]
[1]*Department of Surgery, Vascular Diseases Center, University of Ferrara, Ferrara, Italy*
[2]*Department of Anatomy, University of Rome, Rome, Italy*

Chronic venous disease (CVD), mainly due to venous reflux or, sometimes, to venous outflow obstruction, produces a microcirculatory overload leading to the impairment of venous drainage. Venous drainage depends primarily on a major hemodynamic parameter called trans-mural pressure (TMP). TMP is increased in patients affected by CVD, leading to impaired tissue drainage, and, consequently, facilitating the beginning of the inflammatory cascade. Increased TMP determines red blood cell extravasation and either dermal hemosiderin deposits or iron laden-phagocytes. Iron deposits are readily visible in the legs of all patients affected by severe CVD. Local iron overload could generate free radicals or activate a proteolytic hyperactivity of metalloproteinases (MMPs) and/or downregulate tissue inhibitors of MMPs. These negative effects are particularly evident in carriers of the common HFE gene's mutations C282Y and H63D, because intracellular iron deposits of mutated macrophages have less stability than those of the wild type, inducing a significant oxidative stress. It has been demonstrated that such genetic variants increase the risk of ulcers and advance the age of ulcer onset, respectively. The iron-dependent vision of inflammation in CVD paves the way to new therapeutic strategies including the deliberate induction of iron deficiency as a treatment modality for non-healing and/or recurrent venous leg ulcers. The inflammatory cascade in CVD shares several aspects with that activated in the course of multiple sclerosis, an inflammatory and neurodegenerative disease of unknown origin in which the impairment of cerebral venous outflow mechanisms has been recently demonstrated.
[Int Angiol 2008;27:361-9]

Key words: **Veins - Varicose ulcer - Iron overload - Inflammation - Multiple sclerosis.**

Impaired venous drainage of the lower extremities, mainly due to venous reflux or, sometimes, to venous outflow obstruction, determines a cascade of pathologic events clinically graded by the clinical class (C) of the CEAP classification of chronic venous disease (CVD).[1] Varicose veins is the more frequent clinical sign, class C2; when edema complicates varicose veins, the clinical picture is graded as C3 and when pigmentation, lipodermatosclerosis and other skin changes occur they are classified as C4. A small, but significant, number of the affected patients will develop venous ulcers, whose overall prevalence in Western countries is between 1% and 2% with an estimated cost only for medication of about $ 1 billion/year in the United States and of 14% of the National Health Service (NHS) costs in the United Kingdom.[1-9] Healed ulcer is graded as C5 and active ulcer as C6.[2, 6-10]

Venous function of the lower limbs is a difficult entity to quantify. Many tests have been developed in an attempt to separate normal from abnormal function, including ambulatory venous pressure (AVP), foot volumetry, photoplethysmography and air plethysmography. Unfortunately, none of these methods can completely separate patients and limbs by clinical severity of the disease.[5, 11]

The decrease in venous pressure occurring during exercise represents the functional reserve of the venous system of the lower limbs and closely correlates with the clinical class of chronic venous insufficiency. Although some overlap exists between AVP values obtained in either healthy or insufficient veins of the lower limbs, such a measure is widely considered the gold standard in the evaluation of venous function.[11-13]

Another limitation of AVP is represented by its invasiveness: we believe that an ideal test should be non invasive and easily repeatable. For this reason, in clinical practice air plethysmography became more and more popular.[14-16]

Fundings.—Research supported by the Italian Ministry for the University and the Scientific Research and by the Foundation Cassa di Risparmio di Ferrara.

Invited lecture Tripartite Meeting, EVF-AVF-UKVF. The Royal Society of Medicine, London, July 1st, 2006.

Conflict of interest. None.

Received on December 12, 2006; resubmitted on November 12, 2007; accepted for publication on January 10, 2008.

Finally, duplex scanning and ultrasonographic techniques permit the exact localization of the venous segments affected by reflux, obstruction and/or the combination of both patterns that lead to microcirculatory overload and impaired tissue drainage.[16-19]

Hemodynamic physiopathology of venous drainage

Drainage of tissues is achieved by both venous and lymphatic systems. Venous drainage depends primarily on a major hemodynamic parameter called transmural pressure (TMP). TMP regulation is essential to tissue life. It eliminates catabolites that are toxic to cells and indirectly allows the surge of arterial blood. It plays a role in balancing the liquid compartments. Venous insufficiency from lack of drainage produces an excess of TMP. It leads to cellular suffering from accumulation of toxic metabolites and ischemia from circulatory slowdown. It also increases the volume of the interstitial and cellular liquid compartment. Clinically, it results in such objective symptoms as edema, hypodermitis, necrosis, and ulceration. There are multiple causes of excessive TMP, but they can be classified into two main groups: 1) too high venous pressure, and 2) too low external pressure (EP).[19, 20]

Transmural pressure

TMP (Figure 1) is the key to the hemodynamic drainage mechanism. It is the differential value between two opposite pressures. One is the so-called EP that presses on the external side of the vessel wall. The other is the so-called internal pressure or lateral pressure (IP) that presses the internal side of the vessel wall. TMP, oncotic pressure, and permeability of the capillaries constitute the triad that determines the exchanges between the intra- and extravascular compartments. When IP of the capillary is low and/or extracapillary pressure is high, TMP is low and favorable to drainage, and *vice versa*. The venous system cannot modify EP, but it can modify IP. Thus, the venous system must continually ensure an optimal TMP for drainage by maintaining a low venous pressure.

When venous pressure increases, TMP increases so that liquids and metabolic wastes from the tissues cannot pass into circulation. Obstacles to the passage of liquids can cause edemas. Intratissue accumulation of toxic metabolites associated with capillary flow slowdown are the key mechanisms possibly leading to the beginning of the inflammatory cascade.

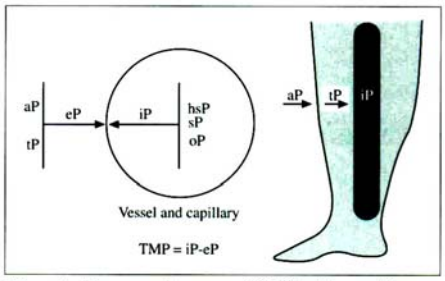

Figure 1.—Transmural pressure (TMP) is the crucial parameter for tissue drainage and venous cross sectional area and varies according to iP and eP modulators (TMP=iP-eP). eP: external pressure (aP: atmospheric pressure + tP: tissue pressure). iP: internal pressure (lateral pressure) (hsP: hydrostatic pressure + sP: static pressure + oP: oncotic pressure [capillary vessel]).

The iron-dependent inflammatory cascade

Impairment of venous hemodynamics, as well as microcirculatory overload with increased TMP, is a necessary, but not sufficient, element for explaining the progression of the disease to the point of a skin lesion.

For such reason, in the past 20 years, a number of adjunctive factors have been investigated to understand the etiology of venous ulceration, but none of them completely explained the entire process. In 1982, Browse *et al.*[21] observed a pericapillary fibrin deposition and speculated that cuffs act as barrier to oxygen diffusion and nutrients, resulting in epidermal cell death. However, these deficiencies in nutrient flow or oxygen diffusion have never been demonstrated. The fibrin cuff may be more properly considered to be a scaffold for tissue reparative process in the course of venous hypertension. The cuff contains fibrin, but also laminin, fibronectin, tenascin and types I and III collagen, encircling the dilated capillary vein.[22] The decline of the fibrin cuff theory led to the investigation of other factors emphasizing inflam-

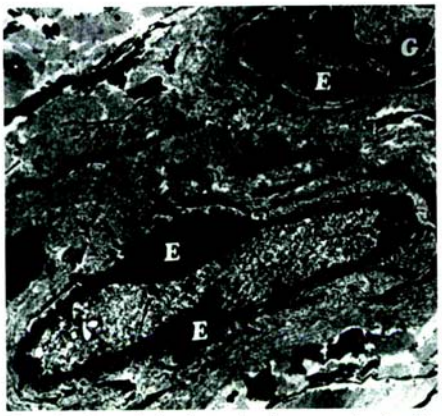

Figure 2.—Transmission electronic microscopy showing dilated capillary in a condition of chronic venous stasis, with slugging of RBC (the cell signaled by G). The endothelial cells can be recognized by the letter E. In this condition, RBC extravasation is a constant features, leading to extravascular hemolysis and consequent hemosiderin deposits. (Magnification ×2000).

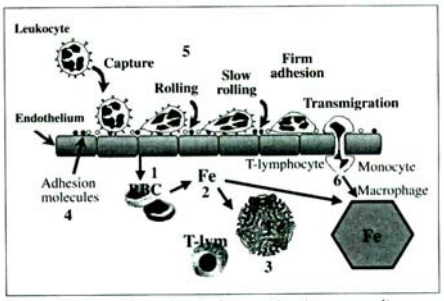

Figure 3.—Iron dependent inflammation in venous diseases: 1) stasis and increased transmural pressure both facilitate RBC extravasation and migration in the extracellular matrix. This leads to extracellular hemolysis and release of free iron (2), immediately inactivated and stored in ferritin-hemosiderin protein system (3) in order to avoid generation of free radicals. Increased iron deposits are potent chemo-attractants inducing adhesion molecules expression on the endothelial cell surface (4), and the consequent chain of capture rolling, adhesion, and transmigration of white cells (5), mainly by T-lymphocyte and monocyte. The latter in the matrix becomes macrophage taking up in turn iron (6).

matory mechanism as amplifiers of the insufficient venous drainage. Recent studies have demonstrated a pivotal role for tissue iron accumulation in inducing and maintaining inflammation in CVD.[2, 23-27] Finally, in the course of severe venous stasis and/or venous leg ulcers, elevated gene expression of several families of matrix metalloproteases (MMPs) and reduced expression of tissue inhibitors of MMPs (TIMPs) have been demonstrated. Such unrestricted MMP proteolytic activity is commonly considered the final executioner of a pathogenetic chain leading to matrix disruption and ulcer development.[28] This event together with the interstitial migration of macrophages has been shown to be a fundamental component of the inflammatory cascade activated in the matrix in the course of CVD.

Iron deposits in CVD cause readily visible brownish dermal areas which sometimes precede, but always surround, ulcers. The origin of increased leg iron stores is the red blood cell (RBC) diapedesis during significant venous stasis (Figure 2). RBCs are degraded by the interstitial macrophages with the released iron incorporated into ferritin. Over time, with increasing overload of iron, the structure of ferritin changes to hemosiderin.[2, 23-27] Ackerman *et al.* in 1988 found a 20-fold higher average of concentration of iron in lower limbs affected by venous ulcers as com-

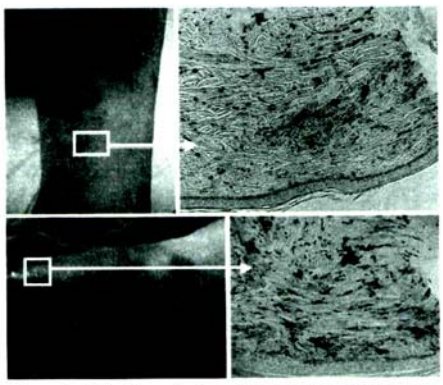

Figure 4.—Skin biopsy in two chronic venous disease cases showing in the subcutaneous tissue increased iron deposits stained in blue, both stored at the extracellular level in hemosiderin deposits and at the intracellular level in the migrated macrophages. (Perl's staining 50x).

pared to the upper arm of the same subjects.[26] The phenomenon of leg hemosiderin deposits seems to be significant for the entire body, because our group found such protein even in the urine of patients affected by severe CVD and venous ulcers.[27]

Increased iron stores and interstitial protein extravasation are potent chemoattractants and presumably represent the initial underlying chronic inflammatory signal responsible for white blood-cell recruitment and migration in the matrix (Figures 3, 4). In 1988, Coleridge Smith *et al.* observed leukocytes trapped in the venous microcirculation secondary to venous hypertension. They speculated that the release of toxic metabolites would lead to tissue damage and ulcer formation. This work paved the way to the investigation of the relationship between CVD and inflammation.[29] The mechanism of white cell migration in the subcutaneous matrix was further elucidated by studies of the expression of adhesion molecules in a model of venous hypertension. Several studies confirmed the expression of these molecules including ICAM, VCAM and selectins.[30-37] Such adhesion molecules block circulating white cells on the vein wall and facilitate transmigration into the tissue. The predominant cells migrating into the extracellular matrix are macrophages and T-lymphocytes.[37-42] Macrophages take up iron accumulated in the tissue and store it in intracellular ferritin-like structures. Intra- and extracellular overload of iron in the tissue could potentially be dangerous for the generation of free radicals (reactive oxygen species [ROS]) due to possible release of free iron from deposits.[2, 23-27, 43, 44] Despite the fact that a reliable ROS assessment is not currently available in the clinical setting, due to their short half life, this hypothesis was further investigated by measuring iron concentration in ulcer exudates. Wenk *et al.*[2] found increased iron levels in exudates from chronic leg ulcers as compared to acute wounds and, more recently, Yeoh-Ellerton *et al.*[43] confirmed this finding. Both authors observed further evidence of ROS activation by measuring significant concentrations of metabolites from oxidative stress.

The final step of the pathogenetic chain leading to matrix disruption and ulcer development involves over-expression of MMPs that are not substantially balanced by their physiologic tissue inhibitors (TIMPs). MMPs cause a substrate specific degradation of matrix components, including collagen, elastin and laminin. Unrestricted MMP activity can lead to matrix break down and ulcer onset.[23, 28] Some experiments demonstrated that local iron overload may induce MMP hyperactivation through the so-called MMP iron driven pathway.[23, 45] Iron release from tissue stores and ROS production are known to be adequate stimuli for MMP production. In our lab, we confirmed the hyperactivation of MMP9, one of the proteases involved in matrix disruption.[2, 23, 28, 46]

Iron-driven inflammation in chronic venous disease and susceptibility genes for venous ulcer complication

The main criticism to the iron hypothesis in venous ulcer development is based on the usual efficiency of the ferritin-ferroxidase system in controlling free iron release.[47-49] For instance, such defensive mechanism is certainly activated in the course of cutaneous hemosiderosis. This kind of skin pigmentation is frequently observed in the skin of the hands of the elderly or readily visible in patients affected by liver hemochromatosis. One could ask why such deposits are capable of causing nothing more than a mild dermal atrophy, whereas iron stores in CVD legs could evolve to tissue disruption. The answer to this objection is in the chronic inflammatory environment of the leg affected by severe CVD. CVD determines a chronic inflammatory state in the skin with edema and trapped leukocytes, protein extravasation, cytokine cascade activation, extensive tissue remodeling with lipodermatosclerosis and hyper-expression of MMPs.[28, 46, 50-53] Regional iron overload becomes a substantial part of the chronic inflammatory process in CVD and thus is absolutely different from sporadic iron deposition.

A further defensive mechanism in response only to iron overload and inflammation is hepcidin, a peptide of 25 amino acids secreted by the liver. Hepcidin binds to ferroportin, the main iron exporter present on the surface of macrophages. After binding, ferroportin is internalized and degraded, leading to decreased export of cellular iron. The post-translational regulation of ferroportin by hepcidin may thus complete the homeostatic loop: iron and interleukin 6, an inflam-

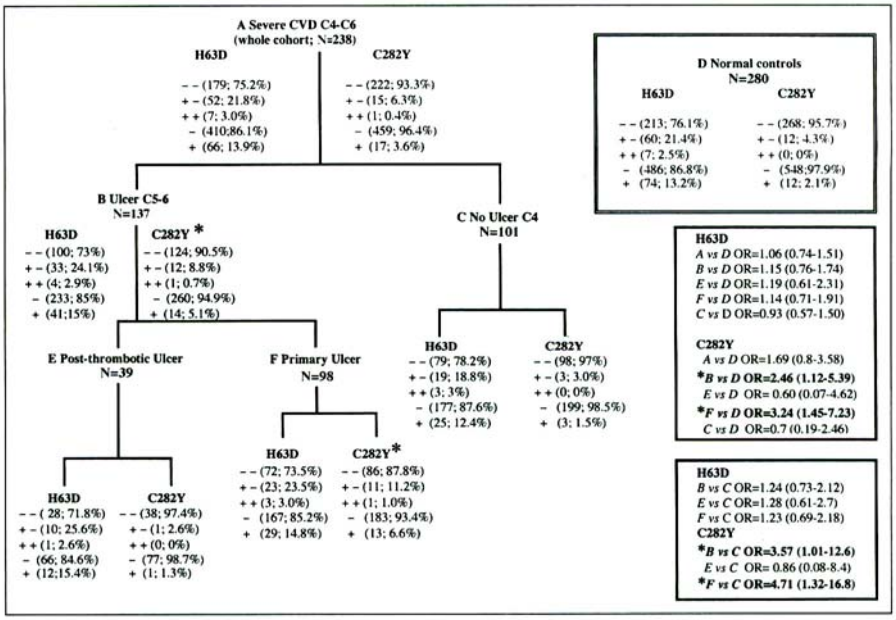

Figure 5.—Assessment of risk of ulceration by comparing the prevalence of ulcer in a group of severe CVD cases, carrying or not carrying the HFE-C282Y variant. The calculated ulcer risk in the entire cohort of CVD including primary and post-thrombotic cases, although certainly appreciable, did not yield statistical significance. In contrast, by sub-setting 199 cases affected by primary CVD, the risk increased by almost five times when the C282Y variant was present.

matory mediator, regulate the secretion of hepcidin, which in turn controls the concentration of ferroportin on the cell surface.[54]

In addition to the iron defensive mechanisms, a shared criticism is that local iron overload is present in the entire cohort of CVD patients and is not an exclusive finding in those destined to ulcer onset. It remains to be explained why iron overload causes lesions in some individuals, whereas it does not in others. In an attempt to understand this patient to patient difference, we investigated the role of hemochromatosis gene (HFE) gene mutations in venous leg ulcers. The HFE mutation, with the C282Y and H63D variants, is the most commonly recognized genetic defect in iron metabolism. The population, especially those of Northern European descent, frequently presents C282Y and H63D heterozygous mutations and subjects showing these genetic variants are generally considered asymptomatic carriers.[55, 56]

From a cohort of 980 consecutive patients affected by severe CVD (CEAP clinical classes C4-C6), we selected 238 cases with the exclusion of any other comorbidity factor potentially involved in wound etiology. The selected patients were subdivided into two groups: one including 137 patients with ulcer (98 primary and 39 post-thrombotic cases) and the other including 101 cases with no skin lesions (class C4). They were completely matched for sex, age and geographical origin with 280 healthy controls. A total of 518 subjects were PCR-genotyped for HFE mutations (C282Y and H63D).

We assessed the prevalence of venous leg ulcer among carriers and wild type and the correspondent risk of ulceration by means of the odds ratio.

In patients affected by venous ulcers the prevalence of the C282Y polymorphic allele was significantly increased compared to healthy controls (5.1% *vs* 2.1%, P=0.035). C282Y mutation significantly increases the risk of ulcer in primary CVD by more than 4 fold. Eighty-six percent of carriers developed venous ulcer primary cases, whereas in wild type the distribution was about 50-50 (Figure 5).

As far as the H63D variant is concerned, further analysis in our patient population demonstrated a more precocious onset of the lesion in carriers of such polymorphism (age of onset: 56±12 years) compared to wild type (64±13 years) (P<0.004) (Figure 5).[24]

The role of HFE mutations in facilitating venous leg ulcer development, demonstrates that, among the broad base of CVD patients, the high-risk minority could be identified in advance by means of a simple blood test that would act as a genetic screening device. Clinical practice could be strongly influenced by the results of the HFE genetic test; presence of the C282Y mutation would strengthen the indications and priorities for surgical correction of superficial venous insufficiency. Then, such preventive measures as elastic stockings, superficial venous surgery, and avoidance of iron-rich foods and dietary supplements, could be utilized in a targeted program of potentially great effectiveness. Thus, primary CVD could be treated more appropriately, before any lesions develop in those patients with a particular genetic haplotype.[57]

The demonstration of gene susceptibility to the development of ulceration, merits further interpretation. We speculate different types of iron management in the macrophages in the affected tissue, in carriers and non-carriers of the HFE mutations, as well as a reduced efficiency of the above reported iron protective mechanisms.

For instance, hepcidin synthesis is regulated by HFE protein and the presence of mutant forms of HFE result in a decreased hepcidin response to an increased iron load.[58] This will result in an increased export of cellular iron.

From this point of view, several studies suggest that intracellular iron deposits in macrophages carrying the C282Y and the H63D mutations are less stable than those in the wild type.[25, 58-60] The mutated macrophages lose the ability to counteract the increased iron export from inside the cell. In addition, it has been demonstrated that the mutated phagocytes, after having taken up the senescent RBCs, release twice the amount of non-transferring-binding iron with respect to wild type. These already known effects of HFE mutations on human macrophages, if speculatively related to our findings, can lead us to assume that the mutated macrophages increase the possibility of generating free iron and free radicals, possibly leading to matrix breakdown and skin lesions.

Our speculations are confirmed by the accelerated date of onset of ulcerations that seem to radically modify the natural history of the disease, whose prevalence is advanced by almost one decade in the H63D carriers. Moreover, the demonstrated genetic susceptibility may explain the greater frequency of venous ulcers in Northern Europe as well as in those areas of the United States that have a high prevalence of Northern European descent. There is a decreased gradient of the HFE variants in Europe from the North to the Mediterranean basin, where venous ulcers are correspondingly less frequent than in Northern Europe, although CVD has the same prevalence.[4, 25, 61]

We demonstrated that in patients affected by severe CVD, the overlapping of local iron overload and the HFE mutation facilitates the occurrence of skin lesions and advances significantly the age of onset of the ulcerative disease. Leg iron overload is due to chronic venous stasis and is not apparently affected by the HFE mutation. In contrast, HFE mutation changes the stability of the intramacrophage ferritin deposits as well as the efficiency of hepcidin regulation system, leading to increased iron efflux. We hypothesize that tissue lesions form from enhanced iron release and free radicals generation.

Finally, it could be hypothesized that the physiologic iron protective mechanisms affected by the HFE mutation, herein described, can be investigated in all diseases characterized by the combination of iron overload and inflammation, as well as the use of deliberate induction of iron deficiency as a treatment modality.[62]

Perspectives

Several studies investigated the relationship between iron overload in the inflammatory areas with increased oxidative stress and other diseases,

such as atherosclerotic cardiovascular disease,[63-65] neurological disease such as Alzheimer disease, Parkinson disease, Friedreich ataxia and other disorders,[66-70] rheumatoid arthritis[71] and infectious diseases.[72, 73] The relationship between increased iron stores and other chronic conditions, such as diabetes[74-76] and cancer,[77-80] have also generated much interest and will continue to be investigated in epidemiologic and mechanistic studies.[81]

However, differently from the above reported disease in which the increased iron stores appear not related to impaired venous function, a strong parallelism between multiple sclerosis (MS) and CVD has been recently shown.[62] In MS, magnetic resonance imaging (MRI) venography and dissection demonstrate invariably a central vein oriented on the long axis of the inflammatory lesion,[82] and both conditions are histologically characterized by perivenous iron deposition, and fibrin cuff.[83] For such reason in the past a role for venous reflux in the complex MS had been hypothesized.[84]

Recent hemodynamic studies identified also in MS several abnormalities in cerebral venous return,[85] including the impairment of the postural mechanism of selection of the extracranial venous out-flow route in MS patients, and its correlation with the disease disability score. In addition, a significant and unsuspected rate of reflux was detected in the extracranial veins of patients affected by MS as compared to healthy controls. The contribution of altered venous hemodynamics either to the impaired drainage of the inflammatory areas, or to the unexplained iron accumulation in the MS plaques could open new prospects in the understanding of the disease.[85]

On the other hand, CVD and MS share some key features, including activation of adhesion molecules, macrophage and T-cell infiltration.[62] As in CVD, RBC extravasation, hemosiderin deposits, and iron-laden phagocytes in MS lesions suggest a pivotal role of iron in the inflammatory cascade. Hemosiderin may appear in the urine in both disorders. As described above in CVD, iron can activate MMPs, and downregulate TIMPs. Serum active MMP9/TIMP-1 ratio is considered an indicator of ongoing MS inflammation. Finally, increased prevalence of CVD and MS is seen in hemochromatosis heterozygotes.

Trials of induced iron deficiency on lesion activity would help to define the roles of iron dependent tissue injury in both disorders. Such a trial would be especially feasible in CVD because of its easily accessible lesions; maybe, in a near future, we could evaluate leg iron stores by non invasive technique (*e. g.* MRI) and start a controlled iron depletion therapy in that patients who have iron overload, with or without HFE mutation. A possible indication could be non-healing and/or recurrent venous leg ulcers, especially in post-thrombotic limbs.

References

1. Eklof B, Rutherford R, Bergan JJ, Carpentier PH, Gloviczki P, Kistner RL *et al.* American venous forum international ad hoc committee for revision of CEAP classification. Revision of the CEAP classification for chronic venous disorders: consensus statement. J Vasc Surg 2004;40:1248-52.
2. Wenk J, Foitzik A, Achterberg V, Sabiwalsky A, Dissemond J, Meewes C *et al.* Selective pick-up of increased iron by deferoxamine-coupled cellulose abrogates the iron driven induction of matrix degrading metalloproteinase 1 and lipid peroxidation in human dermal fibroblasts *in vitro*: a new dressing concept. J Invest Dermatol 2001;116:833-9.
3. Goldman MP, Weiss RA, Bergan JJ. Diagnosis and treatment of varicose veins. A review. Dermatology 1994;31:393-413.
4. Cesarone MR, Belcaro G, Nicolaides AN, Geroulakos G, Griffin M, Incandela L *et al.* Real epidemiology of varicose veins and chronic venous diseases: the San Valentino Vascular Screening Project. Angiology 2002;53:119-30.
5. Nicolaides AN, the International Consensus Group. The investigation of chronic venous insufficiency. A consensus statement. Circulation 2000;102:126-63.
6. Nelzen O, Bergqvist D, Lindhagen A. The prevalence of chronic lower limb ulceration has been underestimated: results of a validated population questionnaire. Br J Surg 1993;83:255-8.
7. Erberth-Willershausen W, Marshall M. Prevalence, risk factors and complications of peripheral venous diseases in the Munich population. Hautartz 1984;35:68-77.
8. Ruckley CV, Evans CJ, Allan PL, Lee AJ, Fowkes FG. Chronic venous insufficiency: clinical and duplex correlation. The Edinburgh Vein Study of venous disorders in the general population. J Vasc Surg 2002;36:520-5.
9. Heit JA, Rooke TW, Silverstein MD, Mohr DN, Lohse CM, Petterson TM *et al.* Trends in the incidence of venous stasis syndrome and venous ulcer: a 25 years population based study. J Vasc Surg 2004;33:1022-7.
10. Callam MJ, Ruckley CV, Harper DR, Dale JJ. Chronic ulceration of the leg: extent of the problem and provision of care. BMJ 1985;290:1855-6.
11. Zamboni P, Portaluppi F, Marcellino MG, Manfredini R, Pisano L, Liboni A. Ultrasonographic assessment of ambulatory venous pressure in superficial venous incompetence. J Vasc Surg 1997;26:796-802.
12. Hosoi Y, Zukowski A, Kakkos SK, Nicolaides AN. Ambulatory venous pressure measurements: new parameters derived from a mathematic hemodynamic model. J Vasc Surg 2002;36:137-42.
13. Eiffel RK, Ashour HY, Lees TA. Comparison of new continuous measurements of ambulatory venous pressure

(AVP) with conventional tiptoe exercise ambulatory AVP in relation to CEAP clinical classification of chronic venous disease. J Vasc Surg 2006;44:794-802.
14. Fukoka M, Sugimoto T, Okita Y. Prospective evaluation of chronic venous insufficiency based on foot venous pressure measurements and air plethysmography findings. J Vasc Surg 2003;38:804-11.
15. Tachibana M, Hiroe T, Kanaoka Y, Ohgi S. Quantitative air plethysmographic venous function and ambulatory venous pressure in patients with primary varicose vein. Int Angiol 2004;23:213-7.
16. Asbeutah AM, Riha AZ, Cameron JD, McGrath BP. Reproducibility of duplex ultrasonography and air plethysmography used for the evaluation of chronic venous insufficiency. J Ultrasound Med 2005;24:475-82.
17. Labropoulos N, Landon P, Jay T. The impact of duplex scanning in phlebology. Dermatol Surg 2002;28:1-5.
18. Coleridge-Smith P, Labropoulos N, Partsch H, Myers K, Nicolaides A, Cavezzi A. Duplex ultrasound investigation of veins in chronic venous disease of the lower limbs—UIP consensus document. Basic principles. Eur J Vasc Endovasc Surg 2006;31:83-92.
19. Navarro TP, Delis KT, Ribeiro AP. Clinical and hemodynamic significance of the greater saphenous vein diameter in chronic venous insufficiency. Arch Surg 2002;137:1233-7.
20. Bochmann RP, Seibel W, Haase E, Hietschold V, Rodel H, Deussen A. External compression increases forearm perfusion. J Appl Physiol 2005;99:2337-44.
21. Browse NL, Burnand KG. The cause of venous ulceration. Lancet 1982;2:243-5.
22. Joshi A, Sloan P. Role of "fibrin" cuffs in chronic nonspecific oral ulceration. Wound Repair Regen 2004;12:18-23.
23. Zamboni P, Scapoli G, Lanzara V, Izzo M, Fortini P, Legnaro A *et al.* Serum iron and MMP-9 variations in limbs affected by chronic venous disease an venous leg ulcers. Dermatol Surg 2005;31:644-9.
24. Zamboni P, Izzo M, Tognazzo S, Carandina S, De Palma M, Catozzi L *et al.* The overlapping of local iron overload and HFE mutation in venous leg ulcers pathogenesis. Free Radic Biol Med 2006;40:1869-73.
25. Zamboni P, Tognazzo S, Izzo M, Pancaldi F, Scapoli GL, Liboni A *et al.* Hemochromatosis C282Y gene mutation increases the risk of venous leg ulceration. J Vasc Surg 2005;42:309-14.
26. Ackerman Z, Seidenbaum M, Loewenthal E, Rubinow A. Overload of iron in the skin of patients with varicose ulcers. Possible contributing role of iron accumulation in progression of the disease. Arch Dermatol 1988;124:1376-8.
27. Zamboni P, Izzo M, Fogato L, Carandina S, Lanzara V. Urine haemosiderin: a novel marker to assess the severity of chronic venous disease. J Vasc Surg 2003;37:132-6.
28. Herouy Y, Mellios P, Banderir E, Dichmann S, Nockowski P, Schopf E *et al.* Inflammation in stasis dermatitis upregulates MMP-1, MMP-2 and MMP-13 expression. J Dermatol Sci 2001;25:198-205.
29. Coleridge Smith PD, Thomas P, Scurr JH, Dormandy JA. Causes of venous ulceration: a new hypothesis. Br Med J 1988;296:1726-7.
30. Takase S, Bergan JJ, Schmid-Schonbein G. Expression of adhesion molecules and cytokines on saphenous veins in chronic venous insufficiency. Ann Vasc Surg 2000;14:427-35.
31. Junger M, Friedrich B, Hahn J, Klyscz T, Muller CA, Schmid-Schonbein GW. Dysregulated L-selectin expression on lymphocytes in patients with chronic venous insufficiency. Clin Hemorheol Microcirc 2001;25:21-30.
32. Rosner K, Ross C, Karlmark T, Skovgaard JL. Role of LFA-1/ICAM-1, CLA/E-selectin and VLA-4/VCAM-1 pathways in recruiting leukocytes to the various regions of the chronic leg ulcer. Acta Derm Venereol 2001;81:334-9.
33. Coleridge-Smith PD. Deleterious effects of white cells in the course of skin damage in CVI. Int Angiol 2002;21:S26-32.
34. Smith PC. The causes of skin damage and leg ulceration in chronic venous disease. Int J Low Extrem Wounds 2006;5:160-8.
35. Bergan JJ, Schmid-Schonbein GW, Smith PD, Nicolaides AN, Boisseau MR, Eklof B. Chronic venous disease. N Engl J Med 2006;355:488-98.
36. Takase S, Pascarella L, Lerond L, Bergan JJ, Schmid-Schonbein GW. Venous hypertension, inflammation and valve remodeling. Eur J Vasc Enovasc Surg 2004;28:484-93.
37. Wilkinson LS, Bunker C, Edwards JC, Scurr JH, Smith PD. Leukocytes: their role in the etiopathogenesis of skin damage in venous disease. J Vasc Surg 1993;17:669-75.
38. Smith PD. Update on chronic venous insufficiency induced inflammatory processes. Angiology 2001;52:S35-42.
39. Pascarella L, Schonbein GW, Bergan JJ. Microcirculation and venous ulcers: a review. Ann Vasc Surg 2005;19:921-7.
40. Nicolaides AN. Chronic venous disease and leukocyte-endothelium interaction: from symptoms to ulceration. Angiology 2005;56:S11-9.
41. Regis G, Bosticardo M, Conti L, De Angelis S, Boselli D, Tomaino B *et al.* Iron regulates T-lymphocyte sensitivity to the INF-gamma/STAT1 signaling pathway *in vitro* and *in vivo*. Blood 2005;105:3214-21.
42. Brusko TM, Wasserfall CH, Agarwal A, Kapturczak MH, Atkinson MA. An integral role for heme oxygenase-1 and carbon monoxide in maintaining peripheral tolerance by CD4+CD25+ regulatory T cells. J Immunol 2005;174:5181-6.
43. Yeoh-Ellerton S, Stacey MC. Iron and 8-isoprostane levels in acute and chronic wounds. J Invest Dermatol 2003;121:918-25.
44. Sullivan JL. Is stored iron safe? J Lab Clin Med 2044;144:280-4.
45. Gurjar MV, Deleon J, Sharma RV, Bhalla RC. Role of reactive oxygen species in IL-1 stimulated sustained ERK activation and MMP-9 induction. Am J Phys 2001;281:H2568-H2574.
46. Herouy Y, May AE, Pornschelegel G, Stetter CH, Grenz H, Preissner KT *et al.* Lipodermatosclerosis is characterized by elevated expression and activation of matrix metalloproteinases: implication for venous ulcers formation. J Invest Dermatol 1988;111:822-7.
47. Wenner A, Leu HJ, Spycher MA, Brunner U. Ultrastructural changes of capillaries in chronic venous insufficiency. Exp Cell Biol 1980;48:1-14.
48. Balla J, Vercellotti GM, Jeney V, Yachie A, Varga Z, Eaton JW *et al.* Heme, heme oxigenase and ferritin in vascular endothelial cell injury. Mol Nutr Food Res 2005;49:1030-43.
49. Reif DW. Ferritin as a source of iron for oxidative damage. Free Radic Biol Med 1992;12:417-27.
50. Ozaki M, Kawabata T, Awai M. Iron release from haemosiderin and production of iron-catalysed hydroxyl radicals *in vitro*. Biochem J 1988;250:589-95.
51. Rogers AA, Burnatt S, Lindholm C, Bjellerup M, Christensen OB, Zederfeldt B *et al.* Expression of tissue-type and urokinase type activator activities in chronic venous leg ulcers. Vasa 1999;28:101-5.
52. Raffetto JD, Vasquez R, Goodwin DG, Menzojan JO. Mitogen-activated protein kinase regulates cell proliferation

in venous ulcer fibroblasts. Vasc Endovasc Surg 2006;1:59-66.
53. Higley HL, Kasander GA, Gerhardt CO, Falanga V. Extravasation of macromolecules and possible trapping of transforming growth factor-beta, in venous ulceration. Br J Dermatol 1995;132:79-85.
54. Nemeth E, Tuttle MS, Powelson J, Vaughn MB, Donovan A, Ward DM *et al.* Hepcidin regulates cellular iron efflux by binding to ferroportin and inducing its internalisation. Science 2004;306:2090-3.
55. McCune CA, Ravine D, Worwood M, Jackson HA, Evans HM, Hutton D. Screening foe hereditary haemochromatosis within families and beyond. Lancet 2003;362:897-8.
56. Beutler E, Felitti VJ, Koziol JA, Ho NJ, Gelbart T. Penetrance of C282Y hereditary haemochromatosis mutation in USA. Lancet 2002;359:211-8.
57. Lanzara S, Catozzi L, De Palma M, Federici F, Palazzo A, Tacconi G *et al.* Mechanism of disease: the inflammatory chain in chronic venous disorders and genetic screening for prevention of venous leg ulcers. Acta Phlebol 2006;7:39-44.
58. Drakesmith H, Schimanski LM, Ormerod E, Merryweather-Clarke AT, Viprakasit V, Edwards JP *et al.* Resistance to hepcidin is conferred by haemochromatosis-associated mutations of ferroportin. Blood 2005;106:1092-7.
59. Drakesmith H, Sweetland E, Schimanski L, Edwards J, Cowley D, Ashraf M *et al.* The hemochromatosis protein HFE inhibits iron export from macrophages. Proc Natl Acad Sci U S A 2002;99:15602-7.
60. Moura E, Noordermeer MA, Verhoeven N, Verheul AFM, Marx JJM. Iron release from human monocytes after erythrophagocytosis *in vitro*: an investigation in normal subjects and hereditary hemochromatosis patients. Blood 1998;92:2511-9.
61. Milman N, Pedersen P. Evidence that the Cys282Tyr mutation of the HFE gene originated from a population in Southern Scandinavia and spread with the Vikings. Clin Genet 2003;64:36-47.
62. Zamboni P. The big idea: iron-dependent inflammation in venous disease and proposed parallels in multiple sclerosis. J R Soc Med 2006;99:1-5.
63. Sullivan JL. Iron and the sex difference in heart disease risk. Lancet 1981;1:1293-4.
64. Zacharski LR, Chow BK, Howes PS, Shamayeva G, Baron JA, Dalman RL *et al.* Reduction of iron stores and cardiovascular outcomes in patients with peripheral arterial disease. A randomized controlled trial. JAMA 2007;297:603-9.
65. Rossi E, McQuillan BM, Hung J, Thompson PL, Kuek C, Beilby JP. Serum ferritin and C282Y mutation of the hemochromatosis gene as predictors of asymptomatic carotid atherosclerosis in a community population. Stroke 2000;31:3015-20.
66. Sipe JC, Lee P, Beutler E. Brain iron metabolism and neurodegenerative disorders. Dev Neurosci 2002;24:188-96.
67. Dekker MC, Giesbergen PC, Njajou OT, wan Swieten JC, Hofman A, Breteler MM *et al.* Mutation in the hemochromatosis gana (HFE), Parkinson's disease and parkinsonism. Neurosci Lett 2003;348:117-9.
68. Sampietro M, Caputo L, Casatta A, Maregalli M, Pellagatti A, Tagliabue J *et al.* The hemochromatosis gene affects the age of onset of sporadic Alzheimer's disease. Neurobiol Aging 2001;22:563-8.
69. Combarros O, Garcia-Roman M, Fontalba A, Fernandez-Luna JL, Llorca J, Infante J *et al.* Interaction of the H63D mutation in the hemochromatosis gene with the apolipoprotein E epsilon 4 allele modulates age at onset of Alzheimer's disease. Dement Geriatr Cogn Disord 2003;15:151-4.
70. Lehmann DJ, Worwood M, Ellis R, Wimhurst VL, Merryweather-Clarke AT, Warden DR *et al.* Iron genes, iron load and risk of Alzheimer's disease. J Med Genet 2006;43:e52.
71. Li J, Zhu Y, Singal DP. HFE gene mutations in patients with rheumathoid arthritis. J Rheumatol 2000;27:2074-7.
72. Marx JJ. Iron and infection: competition between host and microbes for a precious element. Bres Pract Res Clin Haematol 2002;15:411-26.
73. Weinberg ED. Iron and infection. Microbiol Rev 1978;42:45-66.
74. Hua NW, Stoohs RA, Facchini FS. Low iron status and enhanced insulin sensitivity in lacto-ovo vegetarians. Br J Nutr 2001;86:515-9.
75. Lee DH, Folsom AR, Jacobs DR Jr. Dietary iron intake and type 2 diabetes incidence in postmenopausal women: the Iowa Women's Health Study. Diabetologia 2004;47:185-94.
76. Tuomainen TP, Nyyssonen K, Salonen R, Tervahauta A, Korpela H, Lakka T *et al.* Body iron stores are associated with serum insulin and blood glucose concentrations. Population study in 1,013 eastern Finnish men. Diabetes Care 1997;20:426-8.
77. Stevens RG, Graubard BI, Micozzi MS, Neriishi K, Blumberg BS. Moderate elevation of iron level and increased risk of cancer occurrence and death. Int J Canc 2003;145:190-4.
78. Shaheen NJ, Silverman LM, Keku T, Lawrence LB, Roholfs EM, Martin CF *et al.* Associations between hemochromatosis (HFE) gene mutation carrier status and the risk of colon cancer. J Natl Cancer Inst 2003;95:154-9.
79. Kallianpur AR, Hall LD, Yadav M, Christman BW, Dittus RS, Haines JL *et al.* Increased prevalence of the HFE C282Y hemochromatosis allele in women with breast cancer. Cancer Epidemiol Biomarkers Prev 2004;13:205-2.
80. Toyokuni S. Iron and carcinogenesis: from Fenton reaction to target genes. Redox Rep 2002;7:189-97.
81. Hu FB. The iron-heart hypothesis. Search for the iron-clad evidence. JAMA 2007;297:639-41.
82. Tan IL, van Schijndel RA, Pouwels PJ, van Walderveen MA, Reichenbach JR, Manoliu RA *et al.* MR venography of multiple sclerosis. AJNR Am J Neuroradiol 2000;21:1039-42.
83. Schelling F. Damaging venous reflux into the skull or spine: relevance to multiple sclerosis. Med Hypotheses 1986;21:141-8.
84. Adams CW. Perivascular iron deposition and other vascular damage in multiple sclerosis. J Neurol Neurosurg Psychiatry 1988;51:260-5.
85. Zamboni P, Menegatti E, Bartolomei I, Galeotti G, Malagoni AM, Tacconi G *et al.* Intracranial venous haemodynamics in multiple sclerosis. Curr Neurovasc Res 2007;4:252-8.

Corresponding author: Prof. P. Zamboni, Director Vascular Diseases Center, University of Ferrara, 44100 Ferrara, Italy. E-mail: zmp@unife.it